

Cytomegalovirus-related Guillain-Barre syndrome in an adult liver transplant recipient: a case report

Diana Marcela Hoyos-Llanos¹, Nicolas Andres Cortes-Mejia^{3,4,*}, Daniela Lucia Rico-Bolivar^{1,5}, Paula Giraldo-Posada^{3,6}, Francisco Alexander Perez-Rengifo^{1,7}, Alonso Vera-Torres^{1,8}

Abstract

Guillain-Barré syndrome (GBS) is an immune-mediated condition affecting both the motor and sensory spinal roots and peripheral nerves. GBS is a rare entity, with its global incidence being as low as 0.81 to 1.89 cases per 100.000 person-year. Despite its low incidence, GBS have an important morbidity and lethal potential. This syndrome is usually triggered by infections. Due to its clinical presentation heterogeneity and its disease natural history, there is scarce availability of international clinical practice guidelines for the management of this entity. In this report, we present the case of a 67 years-old man on his fifth month after liver transplant (LT), who developed acute non-inflammatory diarrhea followed by sudden ascending symmetric paresia and soles paresthesias. Electrophysiologic studies reported a demyelinating inflammatory polyradiculoneuropathy compatible with GBS, acute severe inflammatory demyelinating polyneuropathy (AIDP) subtype. His neurology deficit was associated with a simultaneous primary Cytomegalovirus (CMV) infection, one of the most common GBS-related infectious agents.

Key words: Guillain-Barre syndrome, Liver transplantation, Cytomegalovirus, Immunosuppression.

Síndrome de Guillain-Barre relacionado a citomegalovirus en un adulto receptor de trasplante hepático: un reporte de caso

Resumen

El síndrome de Guillain-Barré es una condición inmunomediada que afecta tanto a las fibras motoras como a las sensitivas de los nervios periféricos y las raíces dorsales del cordón espinal. El SGB es una entidad global rara cuya incidencia global puede ser tan baja como de 0.81 a 1.89 casos por 100.000 personas año. A pesar de su baja incidencia tiene un importante potencial de causar morbilidad y mortalidad. Este síndrome es usualmente desencadenado por infecciones. Dado que su presentación e historia natural son heterogéneas, hay poca disponibilidad de guías de práctica clínica para su manejo. En este reporte presentamos el caso de un hombre de 67 años, que en su quinto mes postrasplante hepático desarrolló un cuadro de diarrea no inflamatoria seguida de paresia ascendente simétrica y parestesias en las plantas de los pies de aparición súbita. Los estudios electrofisiológicos reportaron una neuropatía desmielinizante inflamatoria compatible con el SGB, particularmente en su variable polineuropatía desmielinizante aguda inflamatoria (PDAl). El déficit neurológico se asoció a una infección primaria simultánea de Citomegalovirus (CMV), una de los agentes más comunes relacionados con el SGB.

Palabras clave: Síndrome de Guillain-Barré, Trasplante Hepático, Citomegalovirus, Inmunosupresión.

Introduction

Liver transplantation (LT) is the best available therapy for patients presenting with advanced cirrhosis and hepatocellular carcinoma¹. Approximately 12.000 LT are done yearly at the United States and in Europe. In our country, Colombia, 243 LT were done in 2022, from these 168 were performed using brain death donors². Infections are a common cause of complications in transplanted patients and are responsible for worse outcomes¹. In LT recipients the CMV is the

most common viral agent, being found in up to 20% of the patients, from which 6% to 30% would develop clinical manifestations³. On the other hand, Guillain-Barre syndrome (GBS), is an immune-mediated inflammatory peripheral neuropathy triggered by infectious agents, commonly *Campylobacter jejuni*, *Haemophilus influenzae*, *Mycoplasma spp*, Cytomegalovirus (CMV), Epstein Barr Virus and Hepatitis E Virus⁴, but other agents have also been linked to GBS like the Influenza Virus A/B and, in tropical areas, the Dengue Virus, the Chikungunya virus and the Zika Virus⁵. GBS global burden

1 Transplant and Hepatology Services, Fundacion Santa Fe de Bogota, Bogotá, Colombia.

2 <https://orcid.org/0000-0001-9240-5547>

3 Transplant and Hepatobiliary Surgery Services, Fundacion Santa Fe de Bogota I, Bogotá, Colombia.

4 <https://orcid.org/0000-0001-9240-5547>

5 <https://orcid.org/0000-0001-9240-5547>

6 <https://orcid.org/0000-0003-1490-1056>

7 <https://orcid.org/0000-0003-1490-1056>

8 <https://orcid.org/0000-0003-4998-2845>

* Autor para correspondencia:

Correo electrónico: nicolascortesmd@gmail.com

Recibido: 25/04/2023; Aceptado: 16/07/2023

Cómo citar este artículo: D.M. Hoyos-Llanos, *et al.* Cytomegalovirus-related Guillain-Barre syndrome in an adult liver transplant recipient: a case report. Infectio 2023; 27(3): 187-191

ranges from 0.81 to 1.89 cases per 100.000 person-year⁶ with a heterogeneous presentation around the world. It affects men more than women (3:1)⁶, a proportion that is kept in Colombia, where 67% of the reported GBS cases are males⁵. This syndrome commonly affects young people, usually under the age of 50⁵. LT teams must be aware that their patients are at increased risk of acquiring plenty of infections associated with GBS, particularly CMV, a pathogen linked to 12.4% of GBS cases⁷. In the next paragraphs a case of a LT recipient who developed GBS preceded by a gastrointestinal CMV disease will be presented.

Case report

A 67-years-old man diagnosed with decompensated cirrhosis (Child Pugh Score A, Supplementary MELD Score 22) secondary to non-alcoholic steatohepatitis and hepatocellular carcinoma, underwent a successful LT procedure on April, 2022; the postoperative period was uneventful and he was discharged after 7 days with a tacrolimus-based immunosuppressive regimen consisting on: prednisolone 10 mg BID, mycophenolate mofetil 1000 mg BID and tacrolimus 5 mg BID. He also had history of arterial hypertension, type II diabetes mellitus, primary hypothyroidism, and chronic obstructive pulmonary disease.

Five months after the transplant, on September 2022, he came to the Emergency Room as he developed sole tingling followed by ascending lower limb weaknesses that progressively reached his upper extremities; these symptoms occurred five days after an acute episode of diarrhea. Inflammatory causes of diarrhea were ruled out as scarce mucus and no leukocytes or red blood cells were detected by coproscopic evaluation. By this time his immunosuppression had been adjusted to tacrolimus 3 mg BID, mycophenolate mofetil 500 mg BID and prednisolone 10 mg QD. Initial physical examination revealed no cranial nerve impairment. Strength was bilaterally decreased in both upper and lower limbs, but was more evident in the right side. Deep tendon reflexes were slightly decreased bilaterally. Negative Babinski's, Hoffman's and Trömmer's signs excluded upper motor neuron compromise. Stocking and glove distributed mild deep and superficial sensation loss was identified. Proprioception was spared. Dysmetria or dysdiadochokinesia were absent. Gait assessment was limited by lower limb weakness. A cervicothoracic magnetic resonance image was obtained and it ruled out acute myelopathy. Electrophysiologic assessment demonstrated poor fiber recruitment on the electromyography and delayed distal latency with decreased wave amplitude and conduction velocities on the neuroconduction test. An electric conduction blockade was seen too, being more pronounced on the lower limbs. Additionally, there were delayed responses (F-wave and H-reflex) in the four extremities (there were absent in both posterior tibial nerves). Excluding the left sural nerve, all the explored neurologic structures in the upper and lower limbs lack sensorial responses (Figure 1A). A lumbar puncture was done and the cerebrospinal

fluid analysis yielded mildly elevated protein count with no pleocytosis. By coupling the clinical presentation with the electrophysiologic studies, the cross-sectional images and the cerebrospinal fluid analysis, the diagnosis of an ongoing acute severe inflammatory demyelinating polyradiculopathy suggestive of GBS, AIDP subtype was done.

At admission, the patient was transferred to the ICU for monitoring and started on intermittent non-invasive mechanical ventilation (NIMV) as he was considered to have an increased risk of respiratory deterioration, particularly because the maxim inspiratory and expiratory pressures were decreased (35% and 25% of the expected value, respectively). Treatment with endovenous human immunoglobulin (IVIG) 0.4 g/kg QD for five days was initiated. Looking for an infectious cause, negative results for a gastrointestinal film-array and *Clostridium difficile* fecal antigen test were obtained, but a positive CMV viral DNA load was detected. As no other infection focus was evident, the CMV was considered the responsible for the neurological symptoms. It stands out that the patient received anti-CMV prophylaxis with valganciclovir 900 mg QD from the fourteenth day after the transplant and, according to our institutional protocol, it was removed after a negative CMV viral DNA load was obtained in August, 2022, three months after the surgery. In this case, a primary host infection, probably arising from the donor liver was diagnosed as the recipient serologic status was negative for the virus, but positive on the donor (D+/R-). Antiviral induction phase with ganciclovir was begun.

By the day twenty of admission and after a brief improvement, the patient acutely deteriorated developing severe lower limb paresia, deglutitory dysmotility for solids and liquids and increased ventilatory effort requiring NMV and, after a while, sustained hypotension that did not respond to volume expansion maneuvers, requiring vasopressor support. A new cycle of IVIG indicated and a fourth generation cephalosporin was initiated as sepsis was suspected. Posteriorly an urinary culture grew a naïve *Proteus mirabilis* and an penicillinase-producer *Escherichia coli*. The antibiotic treatment was consequently adjusted to a second generation cephalosporine. By this moment, the CMV viral DNA load had a negative trend (Figure 2), so the maintenance antiviral phase was begun with valganciclovir BID.

At week four after admission, new electrophysiologic studies revealed a more severe nervous compromise in the lower limbs with some areas of muscular fibrillation and acute positive waves, meaning decreased muscle fiber recruitment. Altogether were interpreted as a combined sensitive and motor subacute axonal polyneuropathy, more prominent in the lower limbs.

After a couple of weeks, the respiratory symptoms seems to be slowly but steadily resolving, but the paresia showed little-to-none signs of recovery. Unfortunately, an extended-spectrum beta-lactamase producer *Escherichia coli* caused

another urinary tract infection, this time progressing to an emphysematous cystitis ruining his recovery because this time invasive mechanical ventilation was required and fourteen days of carbapenemic therapy were needed. He was unable to recover his previous ventilatory performance, so attempting to aid his rehabilitation, a tracheostomy was indicated. Finally, on November, 2022 he was transferred to a long-term care facility where he finally died secondary to a sudden bronchoaspirative episode on March, 2023.

Discussion

Transplants possess the advantage to be the most successful treatment for plenty of morbid, irreversible and potentially lethal diseases; however, these procedures expose the patients to plenty of hazards that the attending medical team must be aware of. These hazards begin at the operating room, during both donor organs retrieving and graft implantation. Then, during the immediate postoperative period, graft dysfunction is a major issue. Lately, the side-effects caused by polypharmacy and the immunosuppressive drugs should be balanced against the risk of infections and graft rejection.

Although all transplants have an increased risk of infection, it varies according to the transplanted organ; pancreas recipients have the highest risk, while liver and kidney transplant

recipients have the lowest risk⁸. The intensity of the immunosuppressive regimen and the time from the surgery are important risk factors. The period between the sixth and the twelfth postoperative months is the most critical for infections, particularly opportunistic ones because during this time the immunosuppressive effect is more intense⁹. We presented a case of a LT recipient who developed GBS as a neurologic consequence of an opportunistic CMV infection in this immunocompromised host. After a LT, the CMV is found in up to 20% of the patients, from which 6% to 30% will develop clinical symptoms³. After the transplant, there are plenty of ways to become infected with CMV; although primary infection is possible, viral reactivation during an episode of graft rejection or secondary to immunosuppression is the most common way¹⁰. Knowing both recipient and donor CMV serologic status is important to identify which patients are at an increased risk for CMV infection, as receiving a seropositive organ being seronegative has the higher odds (D+/R-) (like our patient)¹¹. Due to the high incidence of CMV infection after LT, primary prevention with antiviral prophylaxis must be guaranteed to all recipients from the third to the sixth month after the surgery, but it varies according to each institutional protocol¹². Notwithstanding, even with this strategy it is not always avoidable: a French retrospective cohort involving 20,473 LT recipients demonstrated that 12% acquired CMV within the first 24 months after the transplant. These episodes were commonly

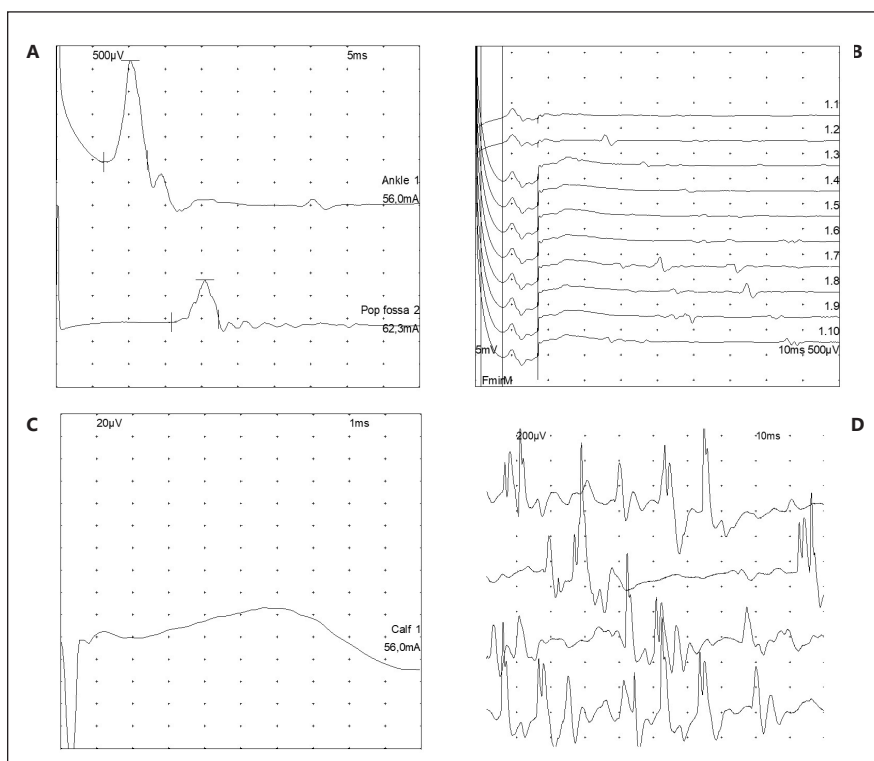


Figure 1. At admission left lower extremity neuroconduction test and electromyography. (A) Left posterior tibial nerve with prolonged latency (15,86 and 6,56 msec at the popliteal fossa and ankle, respectively), markedly decreased potential amplitude (0,9 mV at the popliteal fossa and 2,2 mV at the ankle) and low conduction velocity (45 m/sec at the popliteal fossa). (B) No compound muscle action potential demonstrated by absent F wave at the left posterior tibial nerve. (C) Left sural nerve with bare response during the sensitive neuroconduction test. (D) Tibial anterior nerve demonstrating normal amplitude and duration of the motor unit potentials, but poor fiber recruitment on electromyography.

associated with acute graft rejection episodes, increasing the mortality odds¹³. In LT recipients the diagnosis is confirmed with molecular tests from which the most reliable is the viral DNA load through the polymerase chain reaction technique that has a sensitivity between 84% to 100%¹¹.

In our patient, the CMV became evident because it caused diarrhea followed by an ascending lower limb paralysis with further upper limb and ventilatory compromise and distal paresthesias, classical of GBS. CMV-induced GBS must be differentiated from CMV-induced transverse myelitis or radiculopathy⁴. In the setting of LT, GBS can occur secondary to an immune reconstitution inflammatory syndrome when the immunosuppressive drugs are retrieved or the dose is reduced¹⁴. An infectious agent is identified and linked to GBS in 60% to 70% of the cases. In the largest GBS cohort studied in Europe, 63 (12.4%) over 506 patients had serologic evidence of CMV infection⁷. Physiopathologically it occurs secondary to the existing molecular mimicry between the CMV antigens and the myelin sheath, inducing the host own immune system to cross-react against the membrane surface gangliosides on the neurons' surface; up to 22% of CMV-related GBS have anti-GM2 IgM antibodies¹⁵. GBS affects the peripheral nervous system and has a wide spectrum of clinical presentations according to the involvement of motor, sensorial, autonomic, pain-related or cranial nerve fibers. The disease is monophasic, and the maximum intensity of the symptoms is usually reached at the fourth week after the infectious hit⁴.

Our patient presented with a common GBS variant called AIDP, that affects all types of peripheral nerve fibers¹⁶. AIDP is the most common variant in Colombia, but it varies according to each region⁵. Other variants include the acute motor axonal neuropathy (AMAN), in which patients have pure motor symptoms and the Miller-Fisher syndrome causing the ophthalmoplegia-areflexia-ataxia triad⁴. Other less common and mixed phenotypes have been also described⁴. AIDP is commonly seen in patients with a previous upper respiratory infection

and causes a progressive motor impairment often described as paraparesis or quadriparesis in addition to hypo/areflexia and facial nerve palsy¹⁷; painful paresthesias are reported too⁴.

It usually takes a month for the symptoms to begin to resolve if the proper treatment, either with IVIG or plasma exchange therapy is given¹⁷, however in 10% of the cases, symptoms could relapse after an initial recovery phase, and a new cycle of IVIG is required, like in our case; retreatment have been described with good results, but its real efficacy has never been tested⁴. Most series show that in 80% of the cases it takes two hundred days to achieve the maximum recovery. Unfortunately, 65% will remain with residual symptoms and would require intense rehabilitation interventions and 10% to 15% of patients would not recover an acceptable neurological function. One study involving 79 GBS patients found that 8% died (all older than 60 years), 4% required chronic mechanical ventilation, 9% were unable to walk without help, 17% lost their capability to run and 62% had an almost complete recovery after a year [18]. GBS mortality rate ranges from 1% to 18%^{19, 20}; in Colombian population it is approximately 15%⁵. The most common causes of death included sepsis, pneumonia, severe autonomic dysfunction and acute respiratory distress syndrome⁵. In our patient we strongly believe that he had some degree of autonomic urinary bladder dysfunction predisposing to the recurrent urinary tract infections that ruined his progress, in addition to the GBS relapse after the first IVIG cycle, making very tough to him to recover from his disability. In conclusion, as GBS is an unfrequently described condition in both general and solid organ transplant recipient populations. The evidence for its diagnosis, treatment, and prognosis is scarce. Consequently, prompt detection and early management initiation must be warranted if GBS is suspected. Moreover, careful surveillance is needed as an imbalanced immune microenvironment secondary to immunosuppression and the transplant process by itself could increase the odds of infectious complications and a more ominous recovery. Suspecting and treating uncommon etiological agents is paramount.

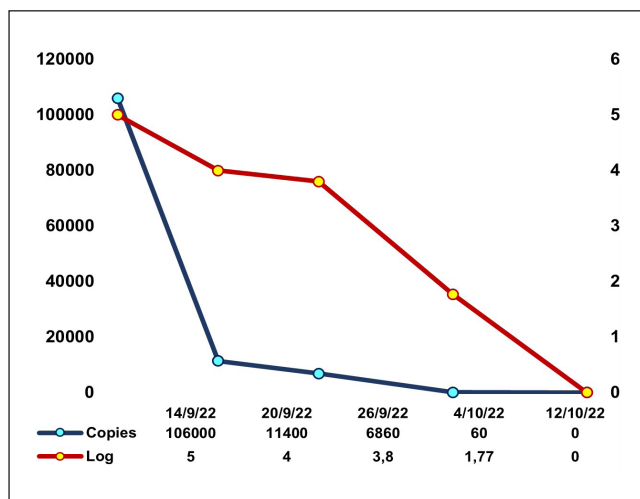


Figure 2. CMV viral DNA load control. The graph shows the trend from the admission to the last measurement after the antiviral treatment was given.

Abbreviations

AIDP: Acute Severe Inflammatory Demyelinating Polyneuropathy
 AMAN: Acute Motor Axonal Neuropathy
 CMV: Cytomegalovirus
 IVIG: Endovenous Human Immunoglobulin
 NIMV: Non-invasive Mechanical Ventilation
 GBS: Guillain-Barré Syndrome
 LT: Liver Transplant

Ethical considerations

The authors adhere to the Helsinki and Istanbul Ethics Statements and they also follow the ethical responsibilities stated by this journal. Patient consent was given, previous to his death and the document was approved by the Fundación

Santa Fe de Bogotá Corporative Ethics Committee for Research and this document is available in case the journal editorial board requires it. Patient confidentiality is guaranteed.

Acknowledgements. This work was founded and supported by the Fundación Santa Fe University Hospital Transplantation Services.

Authors contribution

DH leaded and designed de case report, NC wrote the article and participated in the literature review supporting the discussion and he also submitted the article to the journal, PG and DR compiled the clinical information of the patient to create the report and participated in the literature review that supports the discussion, FP and AV were the senior specialist that review the final product and suggested corrections; FP was the patient attendant hepatologist and AV his surgeon.

References

- Burra Patrizia. Textbook of Liver Transplantation A Multidisciplinary Approach. Textbook of Liver Transplantation. Springer International Publishing; 1st ed, 2022. <https://doi.org/10.1007/978-3-030-82930-8>.
- Instituto Nacional de Salud de Colombia. Informe Ejecutivo Red Nacional de Donación y Trasplantes. 2022, <https://www.ins.gov.co/BibliotecaDigital/Informe-ejecutivo-red-de-donacion-y-trasplantes-2022.pdf>. 2022 [Accessed 17 April, 2023].
- Hakimi Z, Aballéa S, Ferchichi S, Scharn M, Odeyemi IA, Toumi M, et al. Burden of cytomegalovirus disease in solid organ transplant recipients: a national matched cohort study in an inpatient setting. *Transplant Infectious Disease* 2017;19(5). <https://doi.org/10.1111/tid.12732>.
- Van Den Berg B, Walgaard C, Drenthen J, Fokke C, Jacobs BC, Van Doorn PA. Guillain-Barré syndrome: Pathogenesis, diagnosis, treatment and prognosis. *Nat Rev Neurol*. 2014;10(8):469–82. <https://doi.org/10.1038/nrneurol.2014.121>.
- Mahecha, M.P., Ojeda, E., Vega, D.A. et al. Guillain-Barré syndrome in Colombia: where do we stand now?. *Immunol Res* 2017; 65: 72–81. <https://doi.org/10.1007/s12026-016-8816-8>
- Sejvar JJ, Baughman AL, Wise M, Morgan OW. Population incidence of Guillain-Barré syndrome: a systematic review and meta-analysis. *Neuroepidemiology* 2011;36(2):123–33. doi:10.1159/000324710.
- Orlikowski D, Porcher R, Sivadon-Tardy V, Quincampoix JC, Raphaël JC, Durand MC, et al. Guillain-Barré Syndrome following Primary Cytomegalovirus Infection: A Prospective Cohort Study. *Clinical Infectious Diseases* 2011; 52(7): 837–844. <https://doi.org/10.1093/cid/cir074>
- Ljungman Per, Snyderman David, Boeckh Michael. *Transplant Infections*. Fourth Edition, Transplant Infections. Springer International Publishing; 2016.
- Fischer SA. Is This Organ Donor Safe?: Donor-Derived Infections in Solid Organ Transplantation 2019; 99(1): 117–28. <https://doi.org/10.1016/j.suc.2018.09.009>.
- Yadav SK, Saigal S, Choudhary NS, Saha S, Kumar N, Soin AS. Cytomegalovirus Infection in Liver Transplant Recipients: Current Approach to Diagnosis and Management. *Journal of Clinical and Experimental Hepatology* 2017; 7: 144–51 <https://doi.org/10.1016/j.jceh.2017.05.011>
- Lizaola-Mayo BC, Rodríguez EA. Cytomegalovirus infection after liver transplantation. *World J Transplant* 2020; 10(7): 183–190. <https://dx.doi.org/10.5500/wjt.v10.i7.183>
- Kotton CN, Kumar D, Caliendo AM, Huprikar S, Chou S, Danziger-Isakov L, et al. The Third International Consensus Guidelines on the Management of Cytomegalovirus in Solid-organ Transplantation. *Transplantation* 2018; 102(6):900–31. DOI:10.1097/TP.0000000000002191
- Grossi PA, Kamar N, Saliba F, Baldanti F, Aguado JM, Gottlieb J, et al. Cytomegalovirus Management in Solid Organ Transplant Recipients: A Pre-COVID-19 Survey From the Working Group of the European Society for Organ Transplantation. *Transpl Int* 2022; 35:10332. doi: 10.3389/ti.2022.10332.
- Lo Re V, Petridis I, Zivković S, Burgio G, Mularoni A, Milazzo M, et al. Guillain-Barré syndrome after orthotopic liver transplantation: a clinical manifestation of immune reconstitution inflammatory syndrome? *Clinical Neurology and Neurosurgery* 2018; 173:140–143. <https://doi.org/10.1016/j.clineuro.2018.07.021>.
- Jacobs BC, Van Doorn PA, Groeneveld JHM, Tio-Gillen AP, Van Der Meché FGA. Cytomegalovirus infections and anti-GM2 antibodies in Guillain-Barré syndrome. *J Neurol Neurosurg Psychiatry*. 1997;62(6):641–3. DOI:10.1136/jnnp.62.6.641.
- Lunn M, Hughes R. The relationship between cytomegalovirus infection and Guillain-Barré syndrome. *Clin Infect Dis*. 2011; 52(7):845–7. doi: 10.1093/cid/cir082.
- Shang, P., Zhu, M., Wang, Y. et al. Axonal variants of Guillain-Barré syndrome: an update. *J Neurol* 2021; 268: 2402–2419. <https://doi.org/10.1007/s00415-020-09742-2>.
- Dimachkie MM, Barohn RJ. Guillain-Barré syndrome and variants. *Neurol Clin*. 2013; 31(2):491–510. doi:10.1016/j.ncl.2013.01.005.
- Domínguez R, Tolosa P, Patiño A, Quintero A, Collado DK, Miranda MG, et al. Mortalidad asociada al diagnóstico de síndrome de Guillain-Barré en adultos ingresados en instituciones del sistema sanitario mexicano. *Rev Neurol* 2014;58 (01):4–10. <https://doi.org/10.33588/rn.5801.2013370>
- Netto AB, Taly AB, Kulkarni GB, Rao UG, Rao S. Mortality in mechanically ventilated patients of Guillain Barré Syndrome. *Ann Indian Acad Neurol*. 2011; 14(4):262–6. doi:10.4103/0972-2327.91942.