

The first case report of breast actinomycosis due to *Winkia neuii* in Colombia

María Camila Marín-Murillo¹, Daniela Rosero de los Ríos², Sebastian Alejandro Mackenzie-Martinez^{3,*}, Nadia Vanessa Ziade-Sierra⁴

Abstract

Actinomycosis is an uncommon and chronic entity that can cause invasion of various tissues, formation of sinus tracts resembling malignancy, and recurrent nature. Primary actinomycosis of the breast is a rare disease, with few cases reported in the literature. We report the first case of primary actinomycosis of the breast caused by *Winkia neuii* in Colombia in a 47-year-old woman with no significant past medical history.

Keywords: Actinomycosis; breast; *Winkia neuii*

Primer reporte de caso de actinomicosis mamaria por *Winkia neuii* en Colombia

Resumen

La actinomicosis es una entidad crónica e infrecuente que puede causar invasión de diversos tejidos de carácter recurrente con formación de tractos sinusales semejantes a neoplasias. La actinomicosis primaria de la mama hace parte de este grupo de entidades con pocos casos descritos en la literatura. Reportamos el primer caso de actinomicosis primaria de la mama causada por *Winkia neuii* en Colombia en una mujer de 47 años sin antecedentes médicos significativos.

Palabras clave: Actinomicosis; mama; *Winkia neuii*

Introduction

Actinomycosis is a rare and chronic disease that can invade various tissues, form sinus tracts resembling malignancy and relapse nature¹. Actinomyces is an anaerobic gram-positive bacillus rarely implicated in human infections; however, it can cause different types of entities such as abscesses, skin and soft tissue infections, genitourinary infections, and bacteremia². Actinomyces spp. typically colonize the oral, digestive, and genital tracts. *Actinomyces israelii* causes actinomycosis in up–78–80% of cases. *Winkia neuii*, formerly known as *Actinomyces neuii*, is responsible for 17% of all clinical actinomycosis and presents as skin infections, endophthalmitis, and endocarditis^{3,4}. Rarely, *W. neuii* causes primary actinomycosis⁵ and is distinguished from other Actinomyces species by its aerobic growth and lack of branching structures⁶.

Case report

A 47-year-old woman with no significant past medical history presented with moderate-intensity pain in the left breast associated with a sensation of mass and erythema of 4 months du-

ration. Due to these symptoms, breast ultrasound was performed, which showed distortion of the architecture in the lower quadrant of the left breast associated with a non-circumscribed mass with multiple microcalcifications of suspicious appearance. A biopsy of the left breast was performed, and histopathological examination revealed evidence of chronic xanthogranulomatous active mastitis. She was under analgesic management and awaiting evaluation for breast surgery.

The patient presented with worsening pain in the left breast, which was associated with erythema. On admission to the emergency department, the patient denied any history of direct trauma, bites, surgical procedures, or lactation. Physical examination revealed erythematous papules and pustules on the left breast and an irregular mass measuring approximately 5 × 3 cm in the lower outer quadrant without axillary lymphadenopathy or other changes (Figures 1A).

Initial laboratory tests revealed mild leukocytosis (11,900 uL), neutrophilia, no anemia, mild thrombocytosis (500,000 uL), elevated C-reactive protein (5,4 mg/dl), and normal renal function. Breast ultrasound showed fibroglandular tissue

1 Dermatology department, Pontificia Universidad Javeriana – Hospital Universitario San Ignacio. <https://orcid.org/0000-0002-4481-3703>
2 Internal medicine department, Pontificia Universidad Javeriana. – Hospital Universitario San Ignacio. <https://orcid.org/0000-0003-2457-3762>
3 Infectious diseases department, Pontificia Universidad Javeriana. Infectious disease department– Hospital Universitario San Ignacio. <https://orcid.org/0000-0002-2108-7585>
4 Radiology and diagnostic imaging department, Pontificia Universidad Javeriana. Radiology unit– Hospital Universitario San Ignacio. <https://orcid.org/0009-0004-4062-6144>

* Autor para correspondencia:
Correo electrónico: samackenzie@husi.org.co

Recibido: 01/09/2024; Aceptado: 11/08/2025

Cómo citar este artículo: M.C. Marín-Murillo, et al. The first case report of breast actinomycosis due to *Winkia neuii* in Colombia. Infectio 2025; 29(4): 262–264

with a predominance of fat, with a heterogeneous image with cystic content and mobile echoes in its interior in the interline of the inner quadrants with diameters of 38 mm x 24 mm x 42 mm and a volume of 20 cm³ associated with thickening of the adjacent skin and an isoechoic image to the fatty tissue with diameters of 34 mm x 16 mm x 31 mm and a volume of 9.7 cm³ suggestive of chronic collection (Figures 1B).

Based on these findings, the patient was diagnosed with a nonpuerperal breast abscess and started on antibiotic treatment with clindamycin. Incision and drainage were performed, and 36 cm³ of purulent material was obtained. The secretion was sent for culture analyses. Gram stain showed polymorphonuclear cells and Gram-positive cocci. After 48 h, colonies were visible on the anaerobically incubated blood agar. Species identification was performed using matrix-assisted laser desorption ionization time-of-flight mass spectrometry (MALDI-TOF), which identified *Fingoldia magna*, *Peptoniphilus asaccharolyticus*, *Parvimonas micra*, *Prevotella bucae*, and *Winkia neuii*. The treatment was changed to ampicillin-sulbactam.

Owing to persistent local inflammatory changes, a control ultrasound was performed and showed a residual collection of 30 cm³. Only 15 cm³ of hematic material was drained and the patient required a drainage system. In this culture, after 72 hours, colonies were visible on the incubated blood agar and MALDI-TOF showed *Winkia neuii* without isolation of anaerobes. With the diagnostic confirmation of actinomycosis in the breast, the first-line treatment with penicillin was adjusted. The duration was determined to be at least six months. Previously, the patient had received 4 weeks of intravenous antibiotics, with a plan to continue oral antibiotic therapy during the remaining weeks. At present, the patient is clinically improved with adequate pain control and less inflammatory signs in the breast and with tolerance to oral antibiotic treatment with amoxicillin/clavulanate.

Discussion

Primary actinomycosis of the breast, as previously said, is a rare and chronic entity that can, sometimes, resemble malignancy and has a relapsing nature¹. It was first described by Ammentrop in 1893². Actinomyces are anaerobic gram-positive bacilli that can cause a variety of infections, including skin and soft tissue infections, genitourinary infections, and bacteremia¹. Typically, *Actinomyces spp.* colonize the oral, digestive, and genital tracts. *Actinomyces israelii* causes actinomycosis in up to 78-80% of cases, characterized by deep abscesses, tissue fibrosis, and sinus formation³. *Winkia neuii*, formerly known as *Actinomyces neuii*, is responsible for 17% of all clinical actinomycosis and presents as skin infections, endophthalmitis, and endocarditis^{4,5}. *Winkia neuii* rarely causes primary actinomycosis⁶. This species is distinguished from other Actinomyces species by its aerobic growth and lack of branching structures⁶. Actinomycosis can present in all age groups but is frequently seen between 15 and 35 years².

Primary actinomycosis of the breast is a rare disease with few cases reported in the literature. We report the first case of primary actinomycosis of the breast caused by *Winkia neuii* in a 47-year-old woman with no significant medical history in Colombia.

It occurs by direct inoculation of bacteria into the nipple, while the secondary form results from the contiguous extension of infection from another anatomical site, such as extension from pulmonary infection through the thoracic cage affecting the ribs, muscles, and breast². Major risk factors include direct trauma, lactation, piercing, or biting, none of which were present in our patient. Risk factors for primary breast abscesses include smoking, diabetes, and obesity⁷.

Clinical manifestations include recurrent or chronic abscesses of the breast, often in the retroareolar region, draining into the skin through multiple fistulas with purulent or bloody discharge. Mammary actinomycosis has two stages: 1) acute inflammatory, characterized by pain, tumefaction, and erythema, and 2) chronic, with single or multiple indurated nodules, usually transforming into a soft and shifting mass that ruptures toward the skin or adjacent tissues⁸. Clinical manifestations may resemble those of malignancies, such as inflammatory carcinoma or mastitis⁷. If left untreated, fibrosis and architectural distortion of the glandular tissue may develop. may spread to other organs may occur^{1,2}.

For diagnosis, bacterial cultures must be performed to identify gram-positive bacteria; however, 5.5–50% of cultures may be negative for *Actinomyces spp.* These bacteria are slow-growing and must be incubated for at least 10 days before being considered negative. Another diagnostic method is skin biopsy, with 31% of cases diagnosed using this method⁷. Matrix-assisted laser desorption/ionization time-of-flight (MALDI-TOF MS) has emerged as an effective tool for bacterial identification. This technique allows for a faster identification of microorganisms (minutes) compared to the hours or days required by traditional methods. *Winkia neuii* in the present case was identified using MALDI-TOF MS⁹.

It is not uncommon to find other germs in cultures obtained from collections. In two cases reported by Leenstra et al.⁴ they show that other microorganisms can be found, as in the case of our patient. In breast actinomycosis, Bing et al.³ compiled cases published up to 2015 and found that of the 12 cases reported, 6 presented growth of other species such as *Peptoniphilus sp.*, *Actinobaculum schaalii*, alpha-hemolytic *Streptococcus*, *Corynebacterium spp.*, and anaerobic germs, among others. Although other microorganisms could cause mastitis, the prolonged evolution of the disease and the absence of previous surgery or trauma indicate that the other microorganisms found, apart from *Winkia neuii*, fully explain the patient's clinical presentation, making it less likely that they were the causative agent.

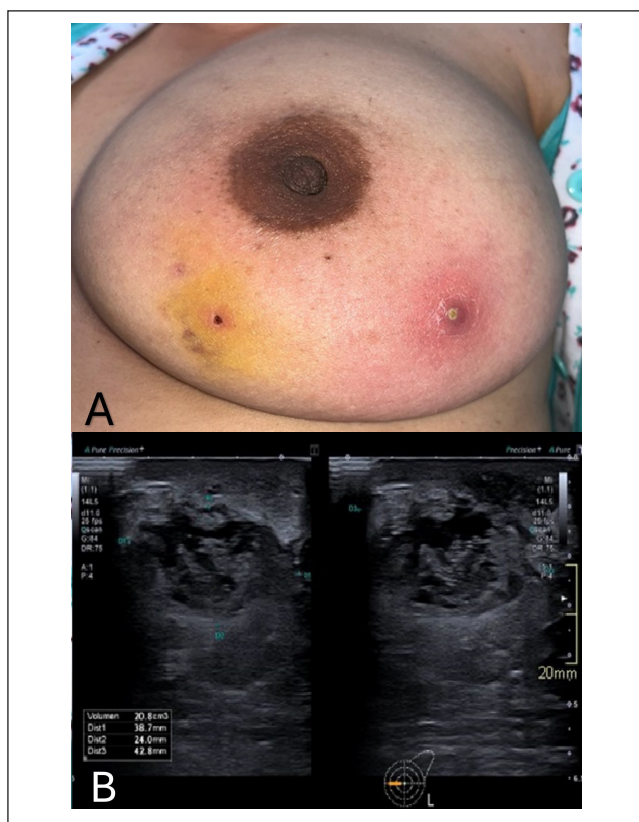


Figure 1. Relevant images for the case. A). Clinical image: Erythematous papules, pustules, and an irregular mass of approximately 5×3 cm in the lower outer quadrant without axillary lymphadenopathy. B). Breast ultrasound: fibroglandular tissue with a predominance of fat component, with a heterogeneous image with a cystic content and mobile echoes in its interior in the interline of the inner quadrants with diameters of $38 \times 24 \times 42$ mm and a volume of 20 cm^3 associated with thickening of the adjacent skin and an isoechoic image to the fatty tissue with diameters of $34 \times 16 \times 31$ mm and a volume of 9.7 cm^3 suggestive of chronic collection.

At this point in time, it is not yet clear whether they play a significant role in the disease process, especially given that the majority of cases previously received antibiotic treatment that covered these germs without achieving complete resolution of the disease.

Imaging often shows enlargement of the mammary gland, skin thickening, and the presence of an irregular mass. Ultrasound may reveal abscesses and fistulas with direct drainage to the skin⁴.

Treatment includes antibiotic therapy. *Actinomyces* species are usually susceptible to β -lactam antibiotics, tetracyclines, and clindamycin. Due to the slow growth of this microorganism, patients require prolonged treatment. Surgical treatment with drainage and excision of the abscess, in combination with medical therapy, is indicated if the patient does not respond well to antimicrobial treatment^{2,5}.

Fortunately, in our patient, drainage of the collection was sufficient, with adequate resolution of the infection with prolonged antibiotic treatment. Given the rarity of this pathology, we believe that it is appropriate to report this case to increase the clinical experience of this entity and to improve the possibility of correctly diagnosing and treating future cases.

Ethical considerations

Protection of persons. Not applicable

Protection of vulnerable populations. Not applicable

Confidentiality. Before this document was created, the patient signed an informed consent form authorizing the presentation, description and publication of this case, while ensuring the protection of their demographic data.

Privacy. All clinical data about the patient that could aid in her identification has been removed from the case description to maintain confidentiality.

Financing. Not applicable

Conflict of interests. The authors have no conflict of interest to declare

Acknowledgments. None

Authors' contribution. M.C. M. M: Contribution to the acquisition and interpretation of relevant clinical data. Direct participation in drafting the clinical case report. D. R. de los R: Contribution to the acquisition and interpretation of relevant clinical data. Direct participation in drafting the clinical case. S. A. M. M: Contribution to the acquisition and interpretation of relevant clinical data. Direct participation in drafting the clinical case. N. V. Z. S: Contribution to the acquisition and interpretation of relevant clinical data. Direct participation in drafting the clinical case. An ultrasound scan was performed on the patient, as visualized in the case report. All authors contributed to read and approved the version of the submitted manuscript.

References

- Zelyas N, Gee S, Nilsson B, Bennett T, Rennie R. Infections Caused by *Actinomyces neuii*: A Case Series and Review of an Unusual Bacterium. *Can J Infect Dis Med Microbiol*. 2016;2016:6017605. doi:10.1155/2016/6017605
- Suranagi V, Agrawal P, Bannur H, Hogade S. Actinomycosis of the breast: A rare association with breast carcinoma. *Saudi J Health Sci*. 2014;3(1):53. doi:10.4103/2278-0521.130212
- Bing AU, Loh SF, Morris T, Hughes H, Dixon JM, Helgason KO. *Actinomyces* Species Isolated from Breast Infections. *J Clin Microbiol*. 2015;53(10):3247-3255. doi:10.1128/JCM.01030-15
- Leenstra BS, Schaap CCM, Bessems M, Renders NHM, Bosscha K. Primary Actinomycosis in the breast caused by *Actinomyces neuii*. A report of 2 cases. *IDCases*. 2017;8:70-72. doi:10.1016/j.idcr.2017.03.014
- Roustan A, Al Nakib M, Boubli L. Un cas d'actinomycose mammaire primitive à *Actinomyces neuii*. *J Gynecol Obstet Biol Reprod (Paris)*. 2010;39(1):64-67. doi:10.1016/j.jgyn.2009.09.005
- Olson JM, Vary JC. Primary cutaneous *Actinomyces neuii* infection of the breast successfully treated with doxycycline. *Cutis*. 2013;92(6):E3-4. <http://www.ncbi.nlm.nih.gov/pubmed/24416755>
- Gollapalli V, Liao J, Dudakovic A, Sugg SL, Scott-Conner CEH, Weigel RJ. Risk factors for development and recurrence of primary breast abscesses. *J Am Coll Surg*. 2010;211(1):41-48. doi:10.1016/j.jamcollsurg.2010.04.007
- Pinto Paz ME, Biminchumo Sagastegui C, Somocurcio Peralta J, Gómez Ponce V. Actinomycosis mamaria: presentación de un caso clínico. *Revista de Senología y Patología Mamaria*. 2024;37(1):100552. doi:10.1016/j.senol.2023.100552
- Randell P. It's a MALDI but it's a goodie: MALDI-TOF mass spectrometry for microbial identification. *Thorax*. 2014;69(8):776-778. doi:10.1136/thoraxjnl-2014-205349