

# Detection of *Mycoplasma capricolum* subsp. *capripneumoniae* and *Mannheimia haemolytica* as causative agents of pleuropneumonia in goats

Fatemeh Namazi<sup>1,2,\*</sup>, Abdollah Derakhshandeh<sup>1,3</sup>, Sajedah Sajadi Hezaveh<sup>4</sup>, Vida Eraghi<sup>1,5</sup>.

## Abstract

**Objective:** The aim of the study was detection of two major causative agents of pleuropneumonia, *Mycoplasma capricolum* subsp. *capripneumoniae* (Mccp) and *Mannheimia haemolytica*, in goats. To the best of our knowledge, this study is the first investigation of Mccp in Iran.

**Methods:** 50 grossly suspected lungs to pleuropneumonia and 10 healthy samples were collected from Shiraz abattoir.

**Results:** Histopathological evaluation of tissue samples showed various diagnosed pneumonias including 40% bronchointerstitial pneumonia (20 samples), 34% interstitial pneumonia (17 samples), 10% fibrinopurulent bronchopneumonia (5 samples), 12% purulent bronchopneumonia (6 samples) and 4% chronic pneumonia (2 samples). In molecular study, all 50 suspected samples and 10 healthy ones by PCR showed no Mccp positive sample, but the detection rate of *M. haemolytica* in suspected samples was 14% and in healthy lungs was zero.

**Conclusions:** It may be concluded that goats referred to Shiraz abattoir is free of Mccp. Further sampling and molecular testing at the level of suspected herds to CCPP can be useful.

**Key words:** Histopathology, Lungs, *Mycoplasma capricolum* subsp. *Capripneumoniae*, *M. haemolytica*, Pleuropneumonia.

## Detección de *Mycoplasma capricolum* subsp. *capripneumoniae* y *Mannheimia haemolytica* como agentes causales de pleuro-neumonía en cabras

## Resumen

**Objetivo:** El objetivo del estudio fue la detección de dos agentes causantes principales de pleuroneumonía, *Mycoplasma capricolum* subsp. *capripneumoniae* (Mccp) y *Mannheimia haemolytica*, en cabras. Hasta donde sabemos, este estudio es la primera investigación de Mccp en Irán.

**Métodos:** 50 pulmones muy sospechosos de pleuroneumonía y 10 muestras sanas se obtuvieron del matadero de Shiraz.

**Resultados:** La evaluación histopatológica de muestras de tejido mostró varias neumonías diagnosticadas, incluyendo 40% de neumonía broncointersticial (20 muestras), 34% de neumonía intersticial (17 muestras), 10% de bronconeumonía fibrinopurulenta (5 muestras), 12% de bronconeumonía purulenta (6 muestras) y 4% neumonía crónica (2 muestras). En un estudio molecular, las 50 muestras sospechosas y 10 sanas por PCR no mostraron una muestra positiva de Mccp, pero la tasa de detección de *M. haemolytica* en muestras sospechosas fue del 14% y en pulmones sanos fue cero.

**Conclusiones:** se puede concluir que las cabras referidas al matadero Shiraz están libres de Mccp. La realización de muestreo adicional y pruebas moleculares a nivel de rebaños sospechosos para CCPP puede ser útil.

**Palabras clave:** histopatología, pulmones, *Mycoplasma capricolum* subsp. *Capripneumoniae*, *M. haemolytica*, Pleuroneumonía

## Introduction

Respiratory infections are significant causes of death in goats. *Mycoplasma capricolum* subsp. *capripneumoniae* (Mccp) is the causative agent of the classical form of contagious caprine pleuropneumonia (CCPP), one of the most serious diseases in goats with high morbidity and mortality,

causing economic losses in the goat industry<sup>1</sup>. As the disease is readily contagious, a short period of contact is enough for successful transmission and no evidence of indirect contact has been shown. The typical signs of CCPP include pulmonary consolidation, pleurisy and pleuropneumonia<sup>2</sup>. The exact geographical distribution of this disease is unknown by OIE, but it is indicated that CCPP is widely distributed in

1 Department of Pathobiology, School of Veterinary Medicine, Shiraz University, Shiraz, Iran

2 <https://orcid.org/0000-0002-2523-2794>

3 <https://orcid.org/0000-0002-1878-1103>

4 Graduated of School of Veterinary Medicine, Shiraz University, Shiraz, Iran.

5 <https://orcid.org/0000-0002-2116-0367>

\* <https://orcid.org/0000-0002-8849-2497>

\* Autor para correspondencia.

Department of Pathobiology, School of Veterinary Medicine, Shiraz University, P.O. Box 71441-69155, Shiraz, Iran.

Tel: +98 71 32286950 - Fax: +98 71 32286940

Correo electrónico: fnamazi@shirazu.ac.ir

Recibido: 03/12/2019; Aceptado: 31/03/2020

Cómo citar este artículo: F. Namazi, et al. Detection of *Mycoplasma capricolum* subsp. *capripneumoniae* and *Mannheimia haemolytica* as Causative Agents of Pleuropneumonia in Goats. Infectio 2020; 24(4): 208-211

Africa and Asia<sup>3</sup>. Gathering information about the epidemiology of CCPP is useful for diagnosis, treatment and control strategies that have been used to improve knowledge about the distribution of CCPP.

*Mannheimia haemolytica* causes bronchopneumonia and affects sheep and goats. This opportunistic pathogen is found in the upper respiratory system of healthy goats, but stress induced by some situation like heat, overcrowding and transport make the bacteria cause pneumonia<sup>4</sup>. It can cause high economic losses due to treatment costs, slowdown in weight gain and decrease of meat and milk production<sup>5</sup>.

The present study was designed to detect two major causative agents of pleuropneumonia, Mccp and *M. haemolytica*, in grossly suspected goat's lungs in Shiraz abattoir using the histopathological and molecular method.

## Materials and Methods

### Sample collection

50 samples of suspected lungs to pneumonia such as pulmonary consolidation and red discoloration and 10 healthy samples were collected during six months in Shiraz abattoir in southern Iran. The samples were immediately put in sterile plastic bags, placed in cooling boxes and were transported to the microbiology laboratory. Samples of both suspected and healthy lungs were considered for both tissue staining procedure and DNA extraction.

### Histopathological examinations

All tissue samples were fixed in 10% neutral buffered formalin, embedded in paraffin, sectioned at 5 µm in thickness and stained with hematoxylin and eosin (H&E).

### DNA extraction

Briefly, one gram of each lung was separately homogenized in 1 mL distilled water and centrifuged (13000 g, 30 sec). Supernatant was removed and 1.5 mL distilled water was added to the tissue pellet, resuspended and centrifuged (13,000 g, 30 sec). This step was repeated twice for washing the tissues. An amount of 500 µL of lysis buffer (Tris-HCL, EDTA, 0.2% Tween; Sinaclon, Tehran, Iran) and 50 µL proteinase K (Sinaclon) was added and incubated overnight at 37 °C. The enzyme digested samples were mixed with 500 µL of phenol:chloroform:isoamylalcohol (25:24:1) for 15 min. Then, the mixture was centrifuged (10000 g, 10 min). The DNA was purified from the supernatant by adding equal volume of phenol: chloroform:isoamylalcohol (25:24:1) and was centrifuged at 10000 g for 1 min. The DNA was precipitated from the aqueous phase by addition of 2.5 volume of absolute ethanol and incubated at -20 °C for 1 hr. The resultant DNA pellet was washed with 70% ethanol twice, dried and resuspended in 50 µL distilled water. Quality of extracted DNA was checked by Thermo Scientific NanoDrop (USA).

### PCR assay for Mccp

The primer for Mccp was (5' -ATCATTTTAAATCCCTTCAAG-3', 5' -TACTATGAGTAATTATAATATATGCAA-3'). PCR was performed in a Mini-MJ Bio Rad system. The specific amplification was performed in a 50 µL final volume obtained by mixing 34 µL of distilled water, 0.5 µL of dNTP (each at 0.20 mM), 3 µL of MgCl<sub>2</sub> (1.5 mM), 0.5 µL of 10U Taq Buffer (Sinaclon, Iran), 1 µL of each primer (0.4 mM of Mccp-spe-F: 50 -ATCATTTTAAATCCCTTCAAG-30 and Mccp-spe-R, 5'-TACTATGAGTAATTATAATATATGCAA-30 ), 0.5µL Taq DNA polymerase (5.00 U µL<sup>-1</sup>) and 5 µL of the sample. PCR conditions consisted of an initial denaturation step of 2 min at 94 °C, followed by 35 cycles of 30 s at 94 °C, 15 s at 47 °C and 15 s at 72 °C and a final extension step of 5 min at 72 °C<sup>6</sup>. Negative and positive bacterial DNA controls were included for each PCR. The PCR products were subjected to electrophoresis in 1.5% agarose gel containing Gel Red (2µL per 50 gel) and the gel visualized under UV light.

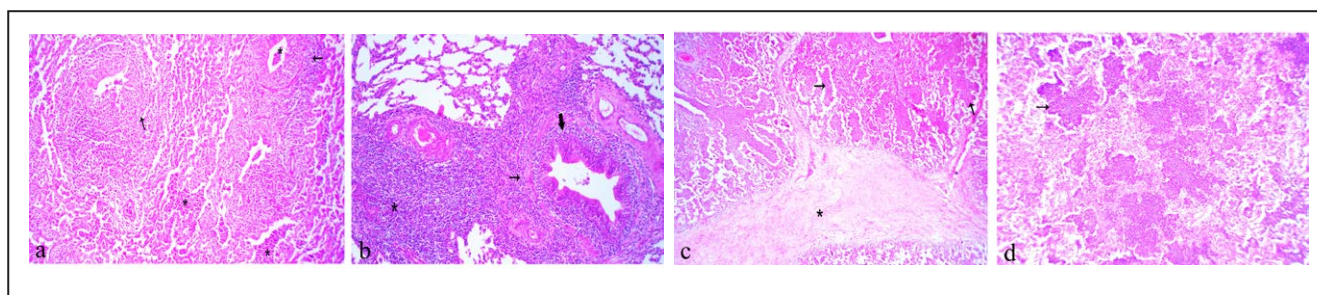
### PCR assay for *M. haemolytica*

The primer for *M. haemolytica* was (5'-GCAGGAGGTGATTATTAAGTGG-3', 5' -CAGCAGTTATTGTCATACCTGAC-3'). PCR condition and thermal cycle was carried out according to previously described by Alexander et al<sup>4</sup>.

## Results

### Gross and histopathological findings

Pulmonary consolidation in anterior and posterior lobes, red discoloration and occasionally pleural involvement, lung surfaces covered with a fibrin layer, were macroscopic lesions of suspected lungs. Histopathological evaluation revealed the most prevalent pneumonia was bronchointerstitial pneumonia, which observed in 40% (20 samples) of suspected samples with lesions including, peribronchiolitis, bronchiolitis, lymphocytic prevascular cuffing (PVC), interlobular septa and alveolar walls thickening due to infiltration of mononuclear cells and connective tissue and infiltration of neutrophils in bronchiolar and alveolar lumina (Figure 1a). Interstitial pneumonia was observed in 34% of suspected lungs with microscopic lesions including BALT, lymphocytic PVC, peribronchiolitis and thickening of alveolar walls because of infiltration of mononuclear cells (Figure 1b). The presence of mononuclear cells and eosinophils with *Muellerius* was observed in one sample. Two suspected lungs also showed type II pneumonocyte hyperplasia. Histopathological findings of samples with fibrinopurulent bronchopneumonia (10%) contained fibrin and numerous neutrophils infiltration in the lumina and thickening of interlobular septa due to fibrin deposition (Figure 1c). In addition, fibrinous thrombi represented in the lymphatic vessels of septa in some cases. 12% of suspected lungs had purulent bronchopneumonia with major lesion of neutrophils infiltration in the alveolar spaces (Figure 1d). Chronic pneumonia in 4% of samples with severe infiltration of mononuclear cells and connective tissue, lymphocytic PVC, BALT, peribronchiolitis and abundant alveolar macrophages was observed. There were no microscopic lesions in healthy lung samples.



**Figure 1.** Histopathological section of lung tissues. **a)** Bronchioalveolar septa thickening with infiltration of neutrophils in bronchioalveolar septa (\*), peribronchiolitis (arrow) and alveolar walls thickening. **b)** Interstitial pneumonia with peribronchiolitis (thin arrow), bronchiolitis (thick arrow) and severe infiltration of mononuclear cells (\*). **c)** Fibrinopurulent bronchopneumonia with neutrophils infiltration in the lumina (arrow) and fibrin deposition in the interalveolar septa (\*). **d)** Purulent bronchopneumonia with numerous neutrophils infiltration in alveolar spaces (arrow). H&E,  $\times 180$ .

### PCR results

Although, the expected band size PCR for Mccp was 316 bp, the PCR showed no Mccp positive sample in all samples, neither suspected CCPP lungs nor healthy ones (Figure 2). The *M. haemolytica* PCR with 206 bp band size was observed in 14% (7 samples) of suspected samples (Figure 3) and no band in healthy lungs. In the 7 positive samples with *M. haemolytica*, lesions consisted of fibrinopurulent bronchopneumonia (four cases), bronchioalveolar pneumonia (two cases) and interstitial pneumonia (one case).

### Discussion

Based on the present findings, the most prevalent pneumonia was bronchioalveolar pneumonia and interstitial pneumonia with major lesions including thickening of interalveolar septa and alveolar walls due to infiltration of mononuclear cells, peribronchiolitis and lymphocytic PVC. In addition to mentioned lesions, infiltration of neutrophils in the lumina was observed in bronchioalveolar pneumonia. Histopathological lesions of CCPP have been reported, including thickening of interalveolar septa, thickening of alveolar walls and lymphocytic PVC<sup>7</sup>. Mondal et al. reported the observation of interalveolar septa thickening, lymphocytic PVC, fibrinous exudates, infiltration of neutrophils and vascular thrombosis, which are the same with observed lesions of fibrinopurulent pneumonia in this study<sup>8</sup>. In an experimental study, Gutierrez et al. reported lesions more in the form of interstitial pneumonia<sup>9</sup>.

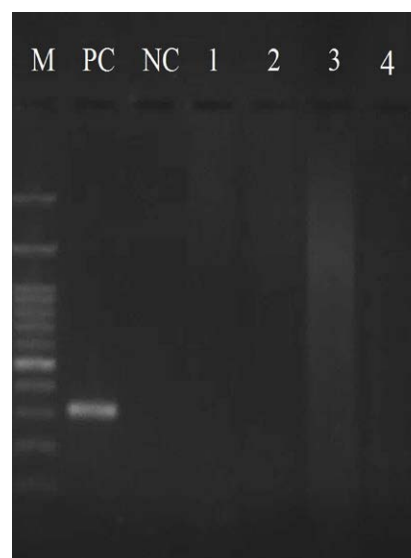Wesonga et al.<sup>10</sup> experimentally inoculated 30 goats with Mccp and observed symptoms and lesions of CCPP, but no positive culture of bacteria was found. Even positive samples in immunohistochemistry were negative by molecular method that is in agreement with our findings.

In Ethiopia, Eshetu et al. reported 31% for the prevalence of CCPP by CFT. Also, they reported that gross and histopathological lesions of the lungs were indicative for pleuropneumonia caused by Mccp<sup>11</sup>. El-Deeb et al. confirmed *Mycoplasma capricolum* subsp. *capripneumoniae* in 55 isolates by PCR, which had showed fibrinous pleuropneumonia<sup>12</sup>. Awan et al. detected 17.65% positive samples for Mccp by PCR along with fibrinous pleuropneumonia and pleurisy in postmortem ex-

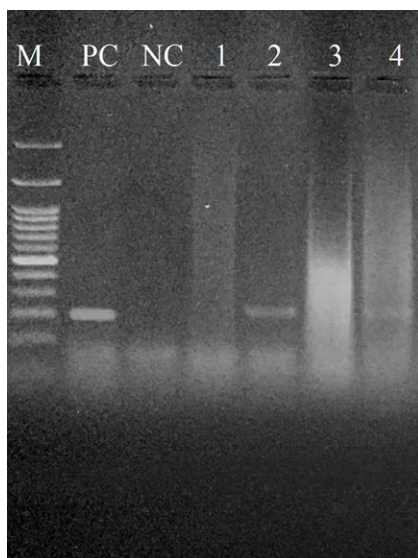
amination<sup>13</sup>. Other study in Turkey revealed 37.5% (12/32) CCPP in lung samples taken from goats<sup>14</sup>. In spite of some evidence of Mccp in mentioned countries, no positive case was detected in this abattoir study. Therefore, it may be needed to perform further studies through more samples and other techniques such as culture to confirm the lack of Mccp in our area.

In the present study, the most observed pneumonia in *M. haemolytica* positive samples by PCR was fibrinopurulent bronchopneumonia. This is relatively consistent with findings of previous studies. Yener et al. represented 15 out of 19 *M. haemolytica* immunopositive pneumonic lungs were fibrinous bronchopneumonia<sup>15</sup>. Also, the study performed by Rawat et al. showed fibrinous bronchopneumonia in pneumonic pasteurellosis<sup>16</sup>.

In conclusion, it seems that goats referring to Shiraz abattoir are free of Mccp and infected with *M. haemolytica* with the prevalence of 14%. As regards there is no epidemiological information on CCPP in our country, serological tests can be used to evaluate the overall distribution of the disease. In addition, sampling and molecular testing at the level of suspected herds to CCPP can be useful.



**Figure 2.** Electrophoretic analysis (1.5% agarose gel) of DNA amplified fragments for Mccp. M: DNA marker 100 bp (Sinaclon). PC: positive control; NC: negative control; Lanes 1-4: lung samples.



**Figure 3.** Electrophoretic analysis (1.5% agarose gel) of DNA amplified fragments for *M. haemolytica*. M: DNA marker 100 bp (Sinaclon). PC: positive control; NC: negative control; Lanes 1 and 3: negative samples; Lanes 2 and 4: positive samples.

## Ethical disclosures

**Protection of human and animal subjects.** No experiments were performed in animal nor humans.

**Confidentiality of data.** Data were anonymized.

**Competing interests.** None declared.

**Funding sources.** None.

**Ethical approval.** This research was approved by the Ethics Committee of the University.

**Conflict of interest.** The authors have no conflicts of interest to declare.

**Acknowledgements.** The authors would like to thank the Research Council of Shiraz University and School of Veterinary Medicine, Shiraz University for financial (Grant number 94GCU4M83832) and technical supports. Also, many thanks to Dr. Francois Thiaucourt and Dr. Mohammad Tabatabaei for sending Mccp DNA and *M. haemolytica* DNA as positive controls, respectively.

**Conflict of interest.** The authors declare no conflict of interest.

## References

- Thiaucourt F, Bolske G, Leneguersh B, Smith D, Wesonga H. Diagnosis and control of contagious caprine pleuropneumonia. *Rev Sci Tech.* 1996;15(4):1415-1429.
- Thiaucourt F, Bolske G. Contagious caprine pleuropneumonia and other pulmonary mycoplasmoses of sheep and goats. *Rev. sci. tech. - Off. int. épizoot.* 1996;15:1397-1414.
- Bolske G, Mattsson JG, Bascunana CR, Bergstrom K, Wesonga H, Johansson KE. Diagnosis of contagious caprine pleuropneumonia by detection and identification of *Mycoplasma capricolum* subsp. *capripneumoniae* by PCR and restriction enzyme analysis. *J Clin Microbiol.* 1996;34(4):785-791.
- Alexander TW, Cook SR, Yanke LJ, Booker CW, Morley PS, Read RR, Gow SP, McAllister TA. A multiplex polymerase chain reaction assay for the identification of *Mannheimia haemolytica*, *Mannheimia glucosida* and *Mannheimia ruminalis*. *Vet Microbiol.* 2008;130(1-2):165-175.
- Ponnuswamy P, Samuel Masilamoni Ronald B, Ranjith Kumar M, Manickam R. Isolation, Identification and AntibioGram of *Mannheimia hemolytica* Associated with Caprine Pneumonia in the Cauvery Delta Region of Tamil Nadu, India. *Int J Curr Microbiol App Sci.* 2017;6(9):3118-3122.
- Woubit S, Lorenzon S, Peyraud A, Manso-Silva L, Thiaucourt F. A specific PCR for the identification of *Mycoplasma capricolum* subsp. *capripneumoniae*, the causative agent of contagious caprine pleuropneumonia (CCPP). *Vet Microbiol.* 2004;104(1-2):125-132.
- Rodríguez F, Sarradell J, Poveda JB, Ball HJ, Fernández A. Immunohistochemical characterization of lung lesions induced experimentally by *Mycoplasma agalactiae* and *Mycoplasma bovis* in goats. *J Comp Pathol.* 2000;123(4):285-293.
- Mondal D, Pramanik AK, Basak DK. Clinico-haematology and pathology of caprine mycoplasmal pneumonia in rain fed tropics of West Bengal. *Small Ruminant Res.* 2004;51:285-295.
- Gutierrez C, Rodriguez JL, Montoya JA, Fernandez A. Clinico-pathological and haematological findings in goat kids experimentally infected simultaneously with *Mycoplasma mycoides* subsp. *capri* and *Mycoplasma mycoides* subsp. *mycoides* (large colony-type). *Small Ruminant Res.* 1999;31:187-192.
- Wesonga HO, Bolske G, Thiaucourt F, Wanjohi C, Lindberg R. Experimental contagious caprine pleuropneumonia: a long term study on the course of infection and pathology in a flock of goats infected with *Mycoplasma capricolum* subsp. *Capripneumoniae*. *Acta Vet Scand.* 2004;45(3-4):167-179.
- Eshetu L, Yigezu L, Asfaw Y. A study on Contagious Caprine Pleuropneumonia (CCPP) in goats at an export oriented abattoir, Debrezeit, Ethiopia. *Trop Anim Health Prod.* 2007;39(6):427-432.
- El-Deeb W, Almujailli AA, Eljalili I, Elmoslemany A, Fayed M. Contagious caprine pleuropneumonia: The first isolation and molecular characterization of *Mycoplasma capricolum* subsp. *capripneumoniae* in the Kingdom of Saudi Arabia. *Acta Trop.* 2017;168:74-79.
- Awan MA, Abbas F, Yasinza M, Nicholas RA, Babar S, Ayling RD, Attique MA, Ahmed Z, Wadood A, Khan FA. First report on the molecular prevalence of *Mycoplasma capricolum* subspecies *capripneumoniae* (Mccp) in goats the cause of contagious caprine pleuropneumonia (CCPP) in Balochistan province of Pakistan. *Mol Biol Rep.* 2010;37(7):3401-3406.
- Çetinkaya B, Kalin R, Karahan M, Atil E, Manso-Silva L, Thiaucourt F. Detection of contagious caprine pleuropneumonia in East Turkey. *Rev. sci. tech. Off. int. Epiz.* 2009;28(3):1037-1044.
- Yener Z, İlhan F, İlhan Z, Sağlam YS. Immunohistochemical detection of *Mannheimia (Pasteurella) haemolytica* antigens in goats with natural pneumonia. *Vet Res Commun.* 2009;33(4):305-313.
- Rawat N, Gilhare VR, Kushwaha KK, Hattimare DD, Farzeen Khan F, Shende RK, Kumar Jolhe D. Isolation and molecular characterization of *Mannheimia haemolytica* and *Pasteurella multocida* associated with pneumonia of goats in Chhattisgarh. *Vet World.* 2019; EISSN: 2231-0916.